
ECHOCARDIOGRAPHY ASSESSMENT OF RIGHT VENTRICLE FUNCTION IN PRE AND POST OPERATIVE PERIOD AFTER CORRECTION OF PULMONARY HYPERTENSION ASSOCIATED PEDIATRIC CONGENITAL HEART DISEASES

R.A. RAKHIMOVA, N.K. ZOKIROV, B.I. SHUKUROV, J.T. PIRNAZAROV

Republican Research Center of Emergency Medicine, Tashkent, Uzbekistan
AKFA Medline University Hospital, Tashkent, Uzbekistan

ЭХОКАРДИОГРАФИЧЕСКАЯ ОЦЕНКА ФУНКЦИИ ПРАВОГО ЖЕЛУДОЧКА В ДО- И ПОСЛЕОПЕРАЦИОННЫЙ ПЕРИОД ПОСЛЕ КОРРЕКЦИИ ЛЕГОЧНОЙ ГИПЕРТЕНЗИИ, АССОЦИИРОВАННОЙ С ВРОЖДЕННЫМИ ПОРОКАМИ СЕРДЦА У ДЕТЕЙ

Р.А. РАХИМОВА, Н.К. ЗОКИРОВ, Б.И. ШУКУРОВ, ДЖ.Т. ПИРНАЗАРОВ

Республиканский научный центр экстренной медицинской помощи, Ташкент, Узбекистан
Клиника «AKFA Medline University Hospital», Ташкент, Узбекистан

Aim. Assessment of right ventricular function in preoperative and postoperative period by using traditional transthoracic echocardiography in children with pulmonary hypertension associated congenital heart defects.

Material and methods. From September 2022 to August 2023, echocardiographic measurements were performed at the AKFA Medline University Hospital on 25 patients with congenital heart defects (17 girls and 8 boys) aged from 6 months to 2 years. Tricuspid annulus plane systolic excursion (TAPSE) in M mode and systolic pulmonary artery pressure (SPAP) was obtained as a main diagnostic echocardiography parameter. All TAPSE results were compared on 3 stage period: preoperative, early postoperative (1–2 days after surgical correction) and late postoperative (1 month after discharge from hospital).

Results. Before the surgery in 12 children SPAP value ranged from 45–55 mm Hg and TAPSE ranged from 12 – to 15 mm (mean 13,5 mm). In 13 children TAPSE ranged from 8–11 mm, till – 2 by Z-score and SPAP was measured more than 55 mmHg. In the period of ICU in 17 children TAPSE consisted of 9–12 mm (more than -2,5 by Z-score) and SPAP decreased to 30 mmHg in early postoperative period after surgical correction of congenital heart defects. In 8 children TAPSE is showed 6–8 mm (more than -3,5 by Z-score) and SPAP 40 to 45 mmHg results. One months after discharging, TAPSE is gradually increased which TAPSE enhanced to 14–17 mm (0 or -1 by Z-score) in 20 children and in 5 patient TAPSE reached to 12–15 mm (till -2 by Z-score).

Conclusion. TAPSE is crucially dropped and well correlated with duration of ICU stay in children after surgical correction of PH associated CHD and gradually increased in the late post-operative period which indicates the risk of right ventricular failure in CHD with high PH in early postoperative period.

Keywords: *pulmonary hypertension, echocardiography, TAPSE, congenital heart defects, SPAP.*

Цель. Оценка функции правого желудочка в предоперационном и послеоперационном периодах с помощью традиционной трансторакальной эхокардиографии у детей с легочной гипертензией, ассоциированной с врожденными пороками сердца.

Материал и методы. С сентября 2022 г. по август 2023 г. в университетской клинике AKFA Medline проведено эхокардиографическое обследование 25 пациентов с врожденным пороком сердца (17 девочек и 8 мальчиков) в возрасте от 6 месяцев до 2 лет. Систolicкую экскурсию плоскости трехстворчатого кольца (TAPSE) в М-режиме и систolicское давление в легочной артерии (SPAP) определяли в качестве основного диагностическо-

го параметра эхокардиографии. Все результаты TAPSE сравнивались на трех этапах: до-операционном, раннем послеоперационном (1–2 дня после хирургической коррекции) и позднем послеоперационном (через 1 месяц после выписки из стационара).

Результаты. До операции у 12 детей значение SPAP колебалось в пределах 45–55 мм рт. ст., TAPSE – от 12 до 15 мм (в среднем 13,5 мм). У 13 детей значение TAPSE колебалось от 8–11 мм до -2 по Z-критерию, SPAP измерялось более 55 мм рт. ст. В период пребывания в отделении интенсивной терапии у 17 детей значение TAPSE составляло 9–12 мм (более -2,5 по Z-score), а SPAP снижалось до 30 мм рт.ст. в раннем послеоперационном периоде после хирургической коррекции врожденных пороков сердца. У 8 детей показатели TAPSE составили 6–8 мм (более -3,5 по Z-score), SPAP – 40–45 мм рт.ст. Через месяц после выписки показатели TAPSE постепенно увеличиваются, при этом у 20 детей увеличились до 14–17 мм (0 или -1 по Z-score), а у 5 пациентов достигли 12–15 мм (до -2 по Z-score).

Заключение. TAPSE резко снижается и хорошо коррелирует с продолжительностью пребывания в отделении интенсивной терапии у детей после хирургической коррекции легочной гипертензии, ассоциированной с ВПС, и постепенно увеличивается в позднем послеоперационном периоде, что указывает на риск развития правожелудочковой недостаточности при ВПС с высокой легочной гипертензией в раннем послеоперационном периоде.

Ключевые слова: легочная гипертензия, эхокардиография, TAPSE, врожденные пороки сердца, SPAP.

https://doi.org/10.54185/TBEM/vol17_iss1/a9

Introduction

Pulmonary arterial hypertension (PAH), or pre capillary pulmonary hypertension (PH), congenital heart disease (CHD) with biventricular hemodynamics, according to the general definition, a condition in which the mean pressure in the pulmonary artery (PA), measured by the method of cardiac catheterization, is 25 mm Hg. and more, pulmonary artery wedge pressure 15 mm Hg. Art. and less, and pulmonary vascular resistance (PVR) – 3 units. Wood/m² and above [1–3]. Despite the fact that there is currently no generally accepted definition of PAH in CHD with univentricular hemodynamics, half a century of world experience in surgical and medical treatment of this category of patients allows us to consider PAH in univentricular hemodynamics as a condition in which the average pressure in the pulmonary artery is 15 mm Hg. Art. and above, PVR – 3 units. Wood/m² or more, and the transpulmonary pressure gradient is 6 mm Hg. and higher [4–5]. In the intensive care setting, especially in patients with CHD, pulmonary vascular disease can complicate the clinical course, even in the rest mean pulmonary arterial pressure does not meet the definition of PH [6]. In patients with a congenital heart disease with an uncorrected left-to-right shunt, increased pulmonary pressure leads to vascular remodeling and dysfunction, resulting in a progressive increa-

se in pulmonary vascular resistance and an increased pressure in the right chambers of the heart [7]. Postoperative PH is often diagnosed based on the peak velocity of the pulse-Doppler in tricuspid regurgitation on echocardiography and pulmonary artery pressure on cardiac catheterization. However, it is difficult to predict postoperative PH after cardiac surgery in patients with CHD because their preoperative characteristics vary [8]. Awareness of the importance of right ventricular function in PAH has increased significantly as it determines the functional state, exercise tolerance and disease outcome in patients. Non-invasive imaging modalities such as echocardiography and cardiac magnetic resonance imaging (MRI) are of paramount importance in the assessment of the right heart. Given the wide availability and low cost, echocardiography is attractive to both patients with PAH and physicians. Tricuspid annulus plane systolic excursion (TAPSE) in M mode is a fairly simple method to calculate the amplitude of systolic movement of the lateral tricuspid annulus. TAPSE has been shown to correlate well with EF RV and TAPSE≥1.8 cm indicates more high ejection fraction, fractional change in area and better survival compared to TAPSE<1.8 cm [9].

Aim of the study is comparative assessment of right ventricular function in preoperative and postoperative period by using traditional transthoracic

cic echocardiography in children with pulmonary hypertension associated congenital heart defects.

Material and methods

From September 2022 to August 2023, echocardiographic measurements were performed at the AKFA Medline University Hospital on 25 patients with congenital heart defects (17 girls and 8 boys) aged from 6 months to 2 years. Siemens Acuson 2000 Doppler ultrasound with a 2.0–5.0 MHz transducer was used as a diagnostic tool. Out of 25 children, 17 children suffered from ventricular septal defect (VSD) with high PAH, 3 children with double outlet right ventricle (DORV), 2 children with total anomalous pulmonary venous return (TAPVR) and 3 children was diagnosed with complete AV canal defects (fig. 1). Tricuspid annulus plane systolic excursion (TAPSE)

in M mode was obtained as a main diagnostic echocardiography parameter. The TAPSE measurement involves obtaining an apical four-chamber view, placing an M-mode line on the lateral annulus of the tricuspid valve (where the leaflet attaches to the right ventricular wall), obtaining an M-mode that tracks and measures the height of the annulus of motion during systole. All TAPSE results were compared on 3 stage period: preoperative, early postoperative (1–2 days after surgical correction) and late postoperative (1 month after discharge from hospital).

As an inclusion criteria only children with 45 mm Hg or above systolic pulmonary artery pressure (SPAP) were included to the study. SPAP was measured from apical four-chamber view via flow of tricuspid regurgitation according to the equation' Bernoulli on the basis that, in the absence of pulmonary stenosis (fig. 2).

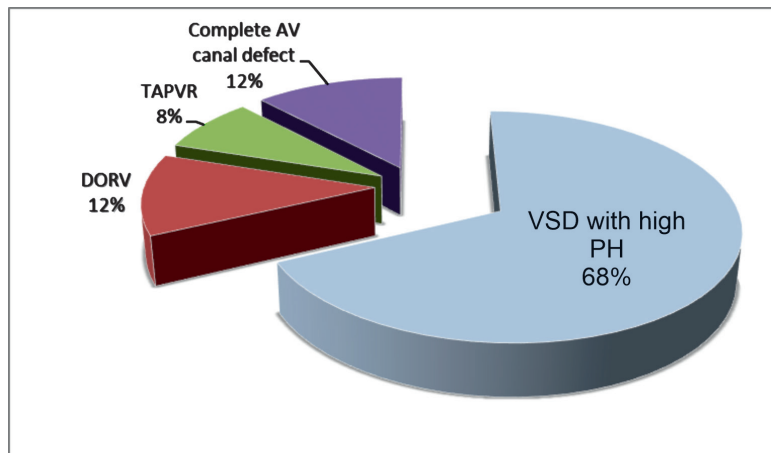


Fig. 1. Pulmonary hypertension associated CHD

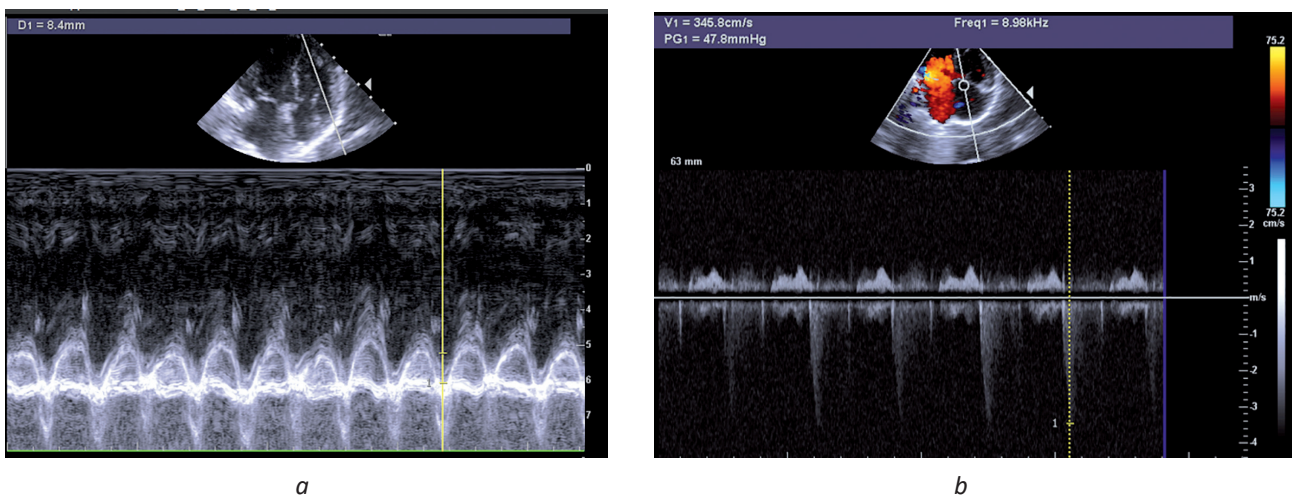


Fig. 2. Echocardiography measurement of TAPSE (a) and SPAP (b) from apical four-chamber view

Results

There were significant statistical differences in the values of TAPSE in the all three stages of examination ($P < 0,05$). According to the echocardiography results, when analyzing preoperative period of trial, in 12 children (10 patient with VSD, 1 patient with supra-cardiac form TAPVR and 1 patient who suffered from complete AV canal defect) SPAP value ranged from 45–55 mm Hg and TAPSE ranged from 12 – to 15 mm (mean 13,5 mm) till – 1,5 by Z-score respectively. In 13 children (1 patient with intra-cardiac form of TAPVR, 7 patient with VSD and 2 patient with complete form AV canal defect) TAPSE ranged from 8–11 mm, till – 2 by Z-score and SPAP was measured more than 55 mmHg. In the period of intensive care unit (ICU) stay of patients, echocardiography measurements were performed during average 3 hours after completing surgical procedure. In 17 children TAPSE showed between 9–12 mm result (more than – 2,5 by Z-score) and SPAP decreased to 30 mmHg in early postoperative period after surgical correction of congenital heart defects. In 8 children TAPSE is significantly decreased to 6–8 mm (more than – 3,5 by Z-score) and SPAP decreased to 40 to 45 mmHg in the stay of ICU. There were slight difference between the patients' period of stay in ICU according to the TAPSE results. The children those TAPSE is more than – 3,5 by Z-score are average from 3 to 5 days stayed in ICU while the patient those TAPSE is more than – 2,5 by Z-score are 2–3 days stayed in ICU department. After 1 months discharge from hospital, all patient came for follow up echocardiography examination to out-patient department. According to the results, in 20 children who underwent surgical correction, TAPSE is gradually increased in comparison to the results in ICU department, which TAPSE enhanced to 14–17 mm (0 or – 1 by Z-score) and in 5 patient TAPSE reached to 12–15 mm (till – 2 by Z-score).

Discussions

In this trial, our results are demonstrated that TAPSE is decreased in the preoperative period in children who suffer from pulmonary hypertension associated CHD and well corellated with the results of SPAP. During the early post-operative period the TAPSE is significantly decreasing in comparison to the results of before the operation, which indicates higher risk of right ventricular dysfunction, while SPAP is gradually decreasing to the normal values. In the follow up echocardiography examination after 1 months discharging from hospital TAPSE is gradually increasing comparing to the results in ICU

department and SPAP is decreased to the normal values. Open cardiac surgery requiring CPB may be an important factor contributing to RV longitudinal function in children with PH. These findings have not been previously reported in this population, and whether this effect is related to CPB or other surgical factors is yet undetermined. Whatever the cause, the altered RV mechanics following repair of CHD may become clinically important in the failing RV and contribute to the poorest outcomes that have been described in this group [10]. Studies investigating tricuspid annular motion specifically in children with PH have shown reduced tricuspid annular displacement in patients with PH and both repaired CHD and structurally normal hearts when compared with age-matched infants and children. TAPSE has been predictive of outcomes in paediatric patients with idiopathic PH but not PH-repaired CHD in studies by Kassem *et al.* and Okumura *et al.* These results contrast with our findings and may reflect a difference in disease severity, management, or patient population [11]. In adults with PH, TAPSE has been shown to be an effective marker of RV function and predictor of outcome, correlating with hemodynamic measures, exercise capacity, and NYHA class. Importantly, TAPSE < 1.8 cm is a strong predictor of mortality in adults with PH [12]. Compared with adult studies evaluating TAPSE, our patients have similar baseline hemodynamic measurements, the dosage of inotropic support and in terms of the duration in ICU stay. In patients with hypoplastic left heart syndrome, TAPSE is significantly reduced following the Norwood procedure despite preserved RV FAC. Cardiac surgery thus results in reduced tricuspid annular motion without obligate reduction in RV performance in hearts exposed to normal PAPs. It is unclear whether exposure of the RV to elevated afterload further reduces TAPSE beyond the effects of surgery alone, and this should be investigated further [13].

Conclusion

Echocardiography is most important, easily obtained and cost reduced diagnostic method in children with CHD. In our study TAPSE is considerably reduced in children after surgical correction of PH associated CHD and gradually increased in the late post-operative period which indicates the risk of right ventricular failure in CHD with high PH.

References

1. Galiè N., Humbert M., Vachiery J.L., Gibbs S., Lang I., Torbicki A. et al. 2015 ESC/ERS Guidelines for the diagnosis and treatment of pulmonary

- hypertension: The joint task force for the diagnosis and treatment of pulmonary hypertension of the European Society of Cardiology (ESC) and the European Respiratory Society (ERS): Endorsed by: Association for European Paediatric and Congenital Cardiology (AEPCC), International Society for Heart and Lung Transplantation (ISHLT). *Eur Heart J*. 2016; 37(1):67.
- Galiè N., Simonneau G. (eds). Updates in pulmonary hyper-tension proceedings of the 5th World Symposium on Pulmonary Hypertension. *J Am Coll Cardiol*. 2013; 62(25, suppl D).
 - Chazova I.E., Martynuk T.V. (eds). Pulmonary hypertension. Moscow; 2015 (in Russ.).
 - Cerro M.J., Abman S., Diaz G., Freudenthal A.H., Freudenthal F., Harikrishnan S. et al. A consensus approach to the classification of pediatric pulmonary hypertensive vascular disease: Report from the PVRI Pediatric Taskforce, Panama 2011. *Pulm Circ*. 2011; 2:286–298.
 - Hosein R.B., Clarke A.J., McGuirk S.P., Griselli M., Stumper O., De Giovanni J.V. et al. Factors influencing early and late outcome following the Fontan procedure in the current era. The «Two Commandments»? *Eur J Cardiothorac Surg*. 2007; 31(3):344–352.
 - Celermajer D.S., Cullen S., Deanfield J.E. Impairment of endothelium-dependent pulmonary artery relaxation in children with congenital heart disease and abnormal pulmonary hemodynamics. *Circulation*. 1993; 87:440.
 - Formigari R., Di Donato R.M., Gargiulo G., Di Carlo D., Feltri C., Picchio F.M., et al. Better surgical prognosis for patients with complete atrioventricular septal defect and Down's syndrome. *Ann Thorac Surg*. 2004; 78:666–672; discussion 672. DOI: 10.1016/j.athoracsur.2003.12.021.
 - Forfia P.R., Vachiéry J.L. Echocardiography in pulmonary arterial hypertension, *Am J Cardiol*. 2012; 110:16S–24S. DOI: 10.1016/j.amjcard.2012.06.012.
 - Forfia P.R., Fisher M.R., Mathai S.C., Houston-Harris T., Hemnes A.R., Borlaug B.A., et al. Tricuspid annular displacement predicts survival in pulmonary hypertension. *American journal of respiratory and critical care medicine*. 2006; 174(9):1034–1041. doi: 10.1164/rccm.200604-547OC.
 - Berger R.M., Beghetti M., Humpl T., Raskob G.E., Ivy D.D., Jing Z.C. et al. Clinical features of paediatric pulmonary hypertension: a registry study. *Lancet*. 2012; 379:537–546.
 - Kassem E., Humpl T., Friedberg M.K. Prognostic significance of 2-dimensional, M-mode, and Doppler echo indices of right ventricular function in children with pulmonary arterial hypertension. *Am Heart J*. 2013;165:1024–1031.
 - Forfia P.R., Fisher M.R., Mathai S.C., Houston-Harris T., Hemnes A.R., Borlaug B.A. et al. Tricuspid annular displacement predicts survival in pulmonary hypertension. *Am J Respir Crit Care Med*. 2006; 174:1034–1041.
 - Petko C., Uebing A., Furck A., Rickers C., Scheewe J., Kramer H.H. Changes of right ventricular function and longitudinal deformation in children with hypoplastic left heart syndrome before and after the Norwood operation. *J Am Soc Echocardiogr* 2011; 24:1226–1232.

БОЛАЛАРДАГИ ЎПКА ГИПЕРТЕНЗИЯСИ БИЛАН КЕЧУВЧИ ТУҒМА ЮРАК НУҚСОНЛАРИ КОРРЕКЦИЯСИДА ОПЕРАЦИЯГАЧА ВА ОПЕРАЦИЯДАН КЕЙИНГИ ДАВРДА ЎНГ ҚОРИНЧА ФУНКЦИЯСИНИ ЭХОКАРДИОГРАФИК БАҲОЛАШ

Р.А. РАХИМОВА, Н.К. ЗОКИРОВ, Б.И. ШУКУРОВ, ДЖ.Т. ПИРНАЗАРОВ

Республика шошилич тиббий ёрдам илмий маркази, Тошкент, Ўзбекистон
«AKFA Medline University Hospital» клиникаси, Тошкент, Ўзбекистон

Мақсад. Ўпка гипертензияси билан кечувчи туғма юрак нуқсонлари бўлган болаларда анъанавий трансоракал эхокардиография ёрдамида операциягача ва операциядан кейинги даврда ўнг қоринча функциясини баҳолаш.

Материаллар ва тадқиқот усуллари. 2022 йил сентябрь ойидан 2023 йил августигача «AKFA Medline University Hospital» клиникасида 6 ойликдан 2 ёшгача бўлган 25 нафар туғма юрак нуқсони бор болаларда (17 нафар қиз ва 8 нафар ўғил бола) эхокардиографик текширувлар ўтказилди. Асосий эхокардиографик диагностик параметри сифатида М режимида олинган трикуспидал клапан фиброз ҳалқаси текислигининг систолик экскурсияси (TAPSE) ва ўпка артериялари систолик босими (SPAP) олинган. Барча TAPSE ва SPAP натижалари 3 босқичда таққосланди: операциядан олдинги, операциядан кейинги эрта (хирургик коррекциядан кейин 1–2 кун ўтгач) ва операциядан кейинги кеч даврлар (касалхонадан чиққандан кейин 1 ой).

Натижалар. Операциядан олдин 12 болада SPAP қиймати 45–55 mmHg ва TAPSE 12–15 мм (ўртача 13,5 мм) оралиғида эди. 13 та болаларда TAPSE 8–11 мм дан, Z-score бўйича – 2 гача қиймат ва SPAP 55 mmHg дан юқори бўлган қийматни ташкил қилди. Интенсив терапия бўлимидаги туғма юрак нуқсонларини хирургик коррекциясидан сўнг операциядан кейинги эрта даврда 17 болада TAPSE 9–12 мм натижани кўрсатган бўлса (Z-score бўйича – 2,5 дан баланд), SPAP қиймати 30 mmHg га камайди. 8 та болада TAPSE 6–8 мм (Z-score бўйича – 3,5 дан баланд) ва SPAP 40 дан 45 mmHg гача бўлган натижаларни кўрсатди. Касалхонадан чиққандан сўнг динамикада бир ой ўтгач, TAPSE аста-секин ўсиб борди, бунда TAPSE 20 та болада 14–17 мм (0 ёки – 1 Z-score бўйича), 5 беморда TAPSE 12–15 мм гача (Z-score бўйича – 2 гача) кўтарилди.

Хулоса. TAPSE болалардаги ўпка гипертензияси билан кечувчи туғма юрак нуқсонлари хирургик коррекциясидан кейин сезиларли даражада пасайди ва интенсив терапия бўлимида даволаниш давомийлиги билан статистик боғлиқлик ҳосил қилган ҳолда операциядан кейинги кечки даврда аста-секин ўсиб борди. Бу операциядан кейинги эрта даврда юқори ўпка гипертензияси билан кечувчи туғма юрак нуқсонларида ўнг қоринча етишмовчилиги хавфини кўрсатади.

Калит сўзлар: ўпка гипертензияси, эхокардиография, TAPSE, туғма юрак нуқсонлари, SPAP.

Information about authors:

Rakhimova Ra'no Abduhakimovna – PhD, DSc, Head of the Department of Ultrasound Diagnostics at Republican Research Center for Emergency medicine.

Zokirov Nodirjon Komiljon o'g'li – MD, Cardiologist and functional diagnostics at AKFA Medline University Hospital.
E-mail: znodirshoh@yahoo.com

Shukurov Bobir Ibragimovich – PhD, Senior Researcher of the Emergency Surgery Department of the Republican Scientific Center of Emergency Medicine.
E-mail: shbobir@gmail.com.
ORCID: 0000-0003-1774-8886

Pirnazarov Jamshidjon Tulkinovich – MD, Head of the Department of Pediatric Cardiac Surgery at AKFA Medline University Hospital.

Received: 13.12.2023

Сведения об авторах:

Рахимова Раъно Абдухакимовна – доктор медицинских наук, заведующая отделением ультразвуковой диагностики Республиканского научного центра экстренной медицинской помощи.

Зокиров Нодиржон Комилжон угли – врач-кардиолог и врач функциональной диагностики многопрофильного медицинского центра Akfa Medline.
E-mail: znodirshoh@yahoo.com.

Шукуров Бобир Ибрагимович – кандидат медицинских наук, старший научный сотрудник отдела экстренной хирургии Республиканского научного центра экстренной медицинской помощи.
E-mail: shbobir@gmail.com.
ORCID: 0000-0003-1774-8886

Пирназаров Джамшиджихон Тулькинович – доктор медицинских наук, заведующий кафедрой детской кардиохирургии AKFA Medline University.

Поступила в редакцию: 13.12.2023